

ORIGINAL RESEARCH

**Gross and microanatomical changes at the weight bearing points of ostrich induced by soil or concrete floor and implications for welfare**

<sup>1</sup>Waugh, E. E., <sup>1</sup>Seabo, D., <sup>1</sup>Aganga, A. A., <sup>1</sup>Dzoma, B. M., <sup>1</sup>Tsopito, C. M., <sup>1</sup>Omphile, U. J., <sup>2</sup>Sebolai, B. and <sup>1</sup>Mathaio, M.

<sup>1</sup>Department of Animal & Production, Botswana College of Agriculture, Private Bag 0027, Gaborone Botswana.

<sup>2</sup>Department of basic Sciences, Botswana College of Agriculture, Private Bag 0027, Gaborone Botswana.

WEE, conceived idea, designed study, collected data, SD, collected data, AAA, designed study, collected data, DBM, collected data, TCM, designed study, collected data, OUJ, designed study, collected data, SB, designed study, MM, collected data, laboratory analysis

**ABSTRACT:**

This study investigated the gross and microanatomical changes occurring at the weight bearing points on the ostrich body surface induced by rearing on soil floor or on concrete floor and the implications for the welfare of the bird. Fourteen ostrich chicks aged nine weeks and raised on concrete were randomly assigned to two rearing groups of seven birds each. The birds (males and females) were raised in a pen 30m x 6m wide with either a soil or a concrete floor. All ostriches were fed a standard commercial ostrich grower diet and watered *ad libitum*. From week 24 two ostriches from each group were slaughtered each month. Photographic evidence and gross examination demonstrated relatively intact skin with superficial erosion of the keratinized layer at the weight bearing points of the ostriches raised on soil floor. In contrast, ostriches raised on concrete floor had observable erosion on the weight bearing points of the 24 week old ostrich. However, lesions of extreme tissue erosion involving the entire skin were observed in the heavier 36 week old ostrich raised on concrete floor. Qualitative analysis of histology slides of the collected specimens revealed extreme skin erosion deep into the subcutis of the tarso-metatarsal pads of the 36 week old ostrich raised on concrete. However, the degree of skin erosion at similar sites of ostriches raised on soil floor was superficial with the surface keratinized layer still intact. Given the well-developed planter digital cushion, the planter digital skin was not subject to excessive wearing in either group of ostriches. For the welfare of ostriches long term and continuous rearing on concrete surface should be strictly avoided as this practice obviously inflicts pain given the degree of tissue erosion observed especially on the tarsal-metatarsal pad.

**Keywords** ostrich, skin erosion, weight bearing areas, soil floor, concrete floor.

Corresponding author: E-mail: [ewaugh@bca.bw](mailto:ewaugh@bca.bw). Tel: +2673650100

Publisher: Botswana College of Agriculture, Gaborone

**INTRODUCTION**

The Ostrich (*Struthio camelus*) is the largest extant biped. It is a flightless bird and is a member of the family of birds known as Ratitae or the running bird. A lot of information has been compiled on different aspects of ostrich production. Research efforts have focused on feeding behaviour, nutrition, disease control and reproduction. Some attention has also been given to ostrich rearing environment with regard health of ostrich. (Kreibich and Sommer, 1995; Aganga *et al.*, 2000; Mushi *et al.*, 1997; Mackie, 2002; Waugh *et al.*, 2007 and

Huchzermeyer, 1994). Of course the above works have had direct positive spin-offs for the welfare of the ostrich. However, the effect of the rearing surfaces on the body of the ostrich has not received much attention.

At rest the ostrich usually assumes sternal recumbency, and can stay in this position for extended periods of time (personal observation). In this position the ostrich body weight is borne by callosities on the ventral sternum, ventral pubis and by the planter pads of the proximal tarso-metatarsal bones, which are overlaid by callosities (Speer, 2011) normally providing a four point

weighting apparatus for the ostrich in sternal recumbency. While standing the weight is borne by the planter digital cushion.

In Botswana, over the past decade, there has been a proliferation of ostrich enterprises. These enterprises were accompanied, almost invariably by appreciable financial outlays, in the construction of pens with concreted floors and also runs made of soil floors. However, limited work has been carried out in the effects of differs floors in ostrich, but there is abundant literature in this area in cattle. Experiences (Speer, 2011) in cattle production have shown that cows raised on hard unyielding abrasive concrete floors sustain excessive wear on claw's weight-bearing points as well as on the sole. This leads to thin sole and exposure of the underlying soft tissue or bone, resulting in the development of infectious skin disorders which are usually painful (Speer, 2011). Hard surfaces are also found to promote claw horn overgrowth, thus creating unbalanced weight bearing within and between the claws of the foot. (Speer, 2011) Land animals tend to prefer soft surfaces for walking and lying down as they find it more comfortable (Speer, 2011). On concrete, bulls lying bouts were less frequent and interrupted attempts to lying down occurred twice as often than on rubber surface. White line and sole hemorrhages in these bulls were also much more severe on concrete, thus affirming the superiority of the rubber floors compared to concrete floors. Graunkle *et al.*, (2011).

The development of claw ulcers and lameness in pigs due to hard, rough concrete floor coupled with the retention of water and urine residue had negative consequences for eating and weight gain. (Carvalho *et al.*, 2009). Pressure exerted on claws was greater on concrete floor, where as overlying concrete with 5mm rubber mats lead to significant pressure relief on the claws thus reducing wear and improving the health and welfare of the animals (Carvalho *et al.*, 2009). The objective of this study was to compare the effects of soil and concrete surfaces on the weight bearing areas of the ostrich's body by assessing the extent of tissue erosion in these areas and implications for the welfare of the rearing birds.

## MATERIALS AND METHODS

The study was conducted at Botswana College of Agriculture Notwane Farm located northeast of the capitol city of Gaborone. The altitude of the area is 987 meters and the coordinates are S24°34.832 and E025°58.394 (GPS: Tom Tom XL, Canada 310) Ostrich chicks were raised according to

Waugh *et al.* (2006). Briefly fourteen ostrich chicks, male and female, aged nine weeks and raised on concrete were blocked into two groups and the groups randomly assigned to two rearing groups (Soil; n = 7 and Concrete; n = 7). The birds were raised in a pen 30m x 6m wide with a sandy loam soil floor or float finished concrete floor. All ostriches were fed a standard commercial ostrich grower diet and watered *ad libitum*. Only 8 birds were sacrificed and the rest were used for another study at age 24 and 36 weeks, two ostriches from each group were humanely slaughtered according to Waugh *et al.* (2006). Specimens of the tissue from sternal and pubic callosities, tarso-metatarsal pads and digital pads including skin and subcutaneous tissue were taken and placed in 10% formal saline until processed. The micro anatomical changes at the weight bearing areas were investigated by first preparing histological slides for observation with the light microscope. Preparation of samples was according to Dellman and Brown (1976). Digital photographs showing histological and gross changes at the weight bearing areas on the body surface were taken using the Canon A640 digital camera. A qualitative assessment of the histology slides was made using histology images (Dellman and Brown, 1976; Muller and Kirk, 1976) to determine the extent of erosion of the skin and subcutaneous layers at these weight bearing areas.

## RESULTS AND DISCUSSION

### *Effects of Soil floor*

The photograph in Figure 1 show the gross appearance of the surface of the tarso-metatarsal pad of the 24 week ostrich raised on soil floor. It is evident from this photograph that the horny surface layer of the skin is still visibly intact with little evidence of erosion of the skin surface. This is confirmed by the histology of the transverse section of the skin of the tarso-metatarsal pad shown in Figure 2 which shows the intact and stratum corneum overlaying the stratum germinativum of the epidermis which overlays the deeper dermis.

Figures 3 show the gross appearance of the tarso-metatarsal pad surface of the 36 week old ostrich raised on soil floor. The horny surface layer is evidently unbroken and intact although showing some signs of surface erosion. This is demonstrated by the superficial to deep histology profile of this tarso-metatarsal pad shown in Figure 4. The continuous stratum corneum (horny layer) overlaying the stratum germinativum is continuous

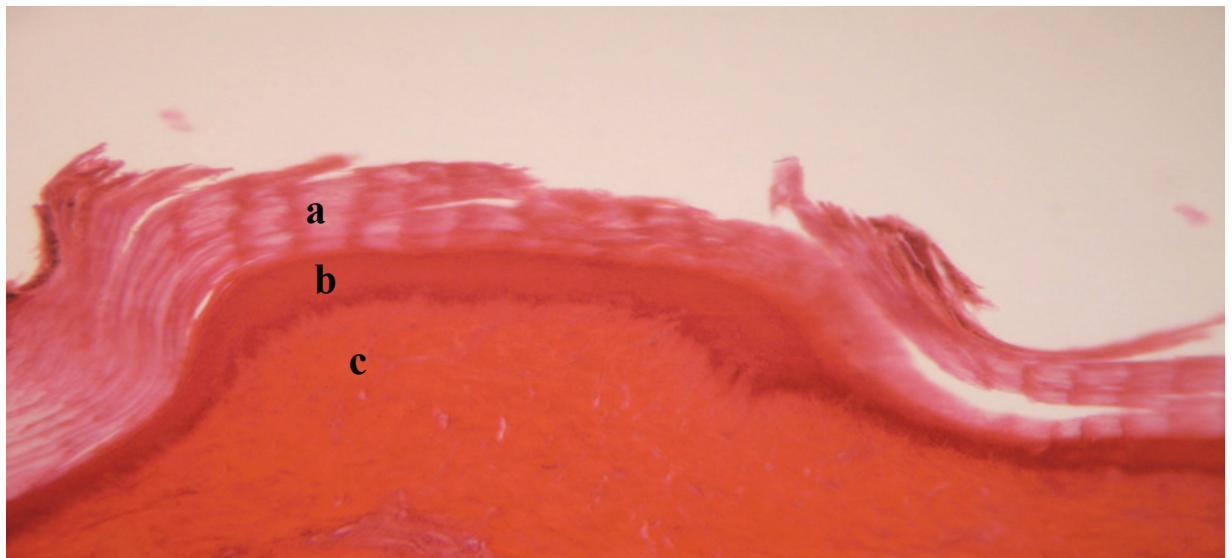
and intact. However the horny layer of this tarso-metatarsal pad compared to the stratum germinativum layer is thinner indicating some erosion on the soil floor as time progressed. The reverse is true in the 24 week old ostrich.

The results clearly indicate that as the ostriches age from 24 to 36 months of age and become progressively heavier the tarso-metatarsal weight

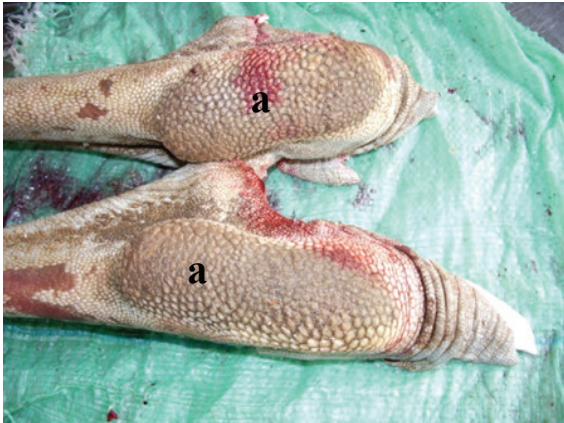bearing surface shows an increasing degree of erosion of the skin surface on soil floor. In spite of this increasing erosive tendency the superficial horny layer shows continuity grossly as well as histologically in all age groups. These findings do indicate that the soil floor as a rearing surface is very gentle on this weight bearing surface of the ostrich.



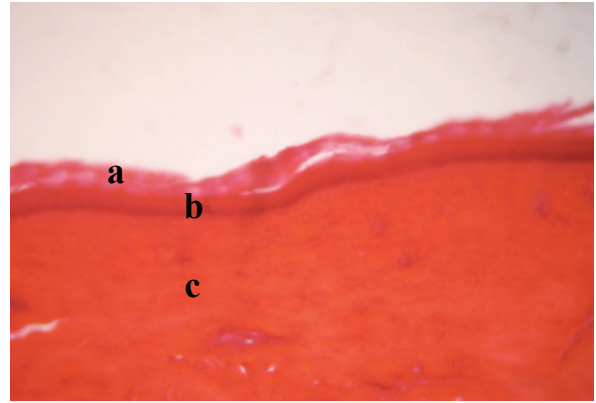
**Figure 1:** Tarso-metatarsal pad of the 24 weeks old ostrich reared on soil floor. a= intact horny layer of the tarso-metatarsal pad



**Figure 2:** Transverse section of the skin of the tarso-metatarsal pad of the 24 weeks old ostrich reared on soil floor. a= stratum corneum ; b= stratum germinativum; c,=dermis



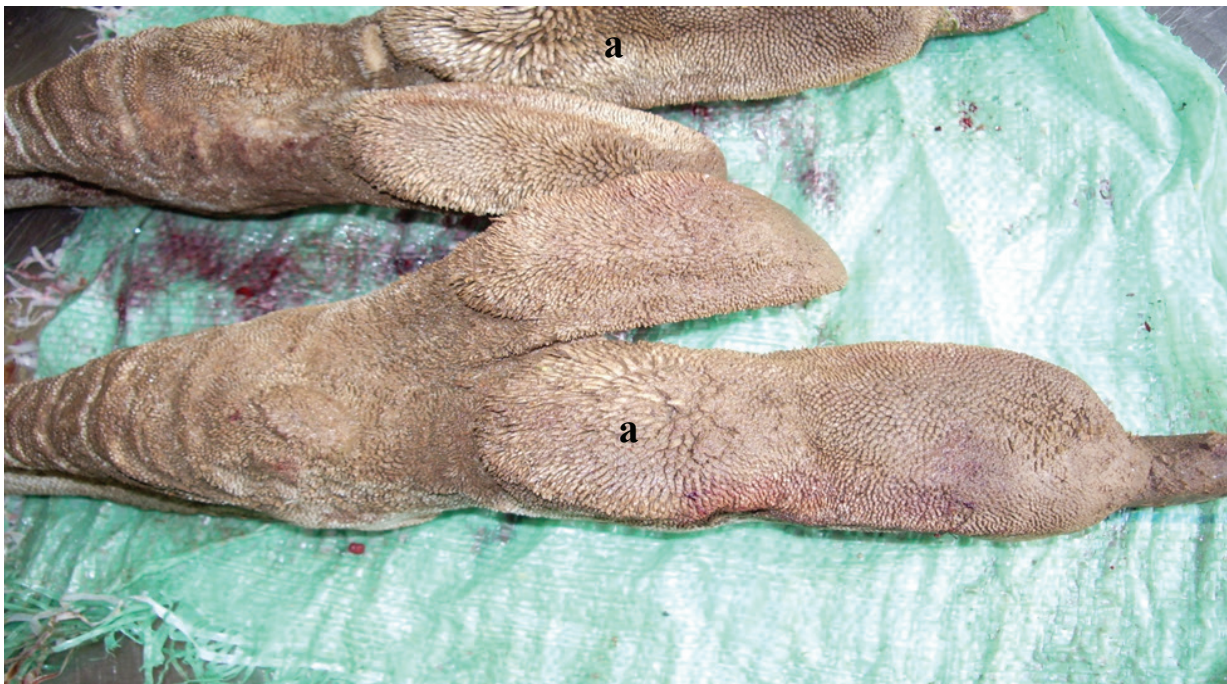**Figure 3:** Tarso-metatarsal pad of the 36 weeks old ostrich reared on soil floor. a= intact horny layer of the tarso-metatarsal pad



**Figure 4:** Transverse section of the skin of the tarso-metatarsal pad of the 36 weeks old ostrich reared on soil floor. a= stratum corneum; b=stratum germinativum; c=dermis

Figure 5 shows the gross appearance of the planter surface of the digital pad of the 36 weeks old ostrich raised on soil floor. Close observation reveals the highly visible horny projections on the planter surface of the digital pad suggesting minimal wear in this weight bearing area.

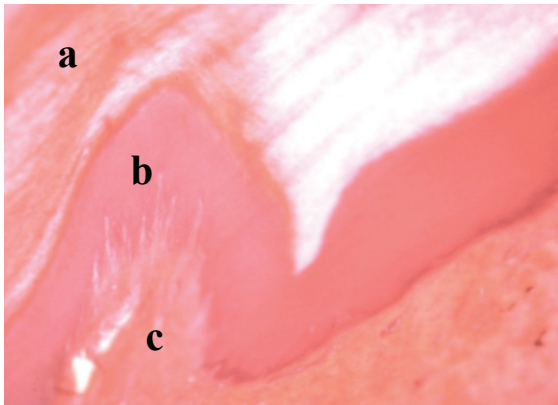
Histological examination of the skin and sub dermis in Figure 6 shows extensive keratinization (horny layer) overlaying the stratum germinativum of the epidermis, demonstrating that erosion of this weight bearing surface is minimal on soil floors.



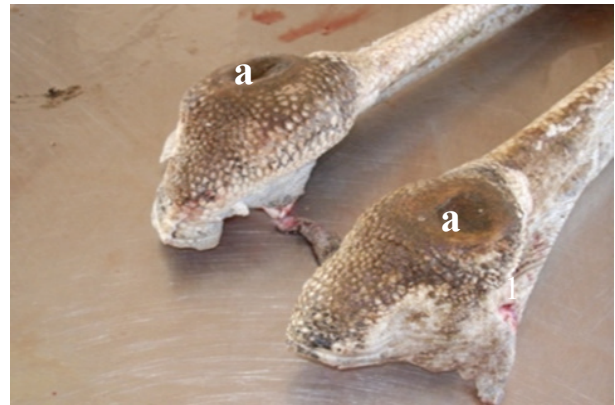**Figure 5:** Planter digital pad of 36 weeks old ostrich reared on soil floor. a=horny surface layer of the digital pad

The minimal degree of skin surface erosion in weight bearing areas on ostriches reared on the soil floor is not surprising as the soil is the surface on which these birds live in the wild. As a rearing

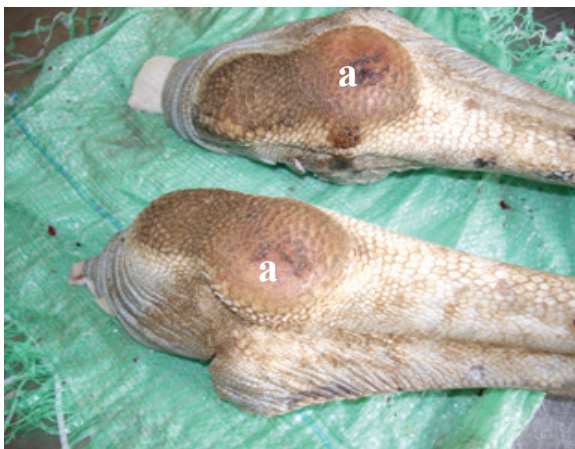surface, soil is usually relatively soft and yielding as opposed to hard and more abrasive surfaces such as concrete (Ackerman, 2011).



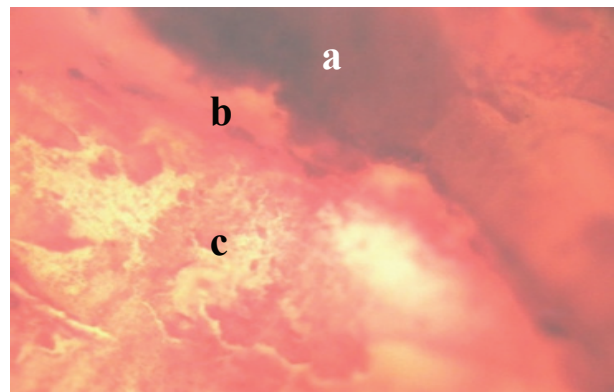
**Figure 6:** Transverse section of the skin of the planter digital pad of the 36 week old ostrich reared on soil floor. a=stratum corneum; b=stratum germinativum; c = dermis



**Figure 8:** The tarso-metatarsal pad of the 36 week old ostrich reared on concrete floor. a=severely eroded skin lesion showing pitting of the surface



**Figure 7.** The tarso-metatarsal pad of the 6 month old ostrich reared on concrete floor with: a = circumscribed erosion of the skin



**Figure 9:** Superficial to deep section of the skin of the tarso-metatarsal pad of the 36 weeks old ostrich reared on concrete floor. a= necrosis in mid lesion ; b=border of necrotic and inflamed tissue; c=sub dermal inflamed and fibrotic tissue

#### *Effects of concrete floor*

The photographs in Figures 7 and 8 show the gross appearance of the tarso-metatarsal pads of the 24 week old and the 36 week old ostrich respectively raised on concrete floor. Already, at 24 weeks old, erosion of the horny surface layer is quite evident. Circumscribed areas of the tarso-metatarsal pad of the 36 week ostrich shows extreme and deep erosion with the superficial horny layer and the deep layers of the skin completely eroded evidenced by the deep pitting of the surface.

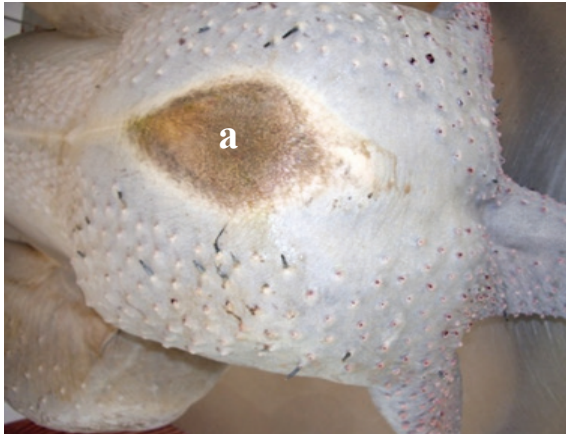Microscopic analysis of the tarso-metatarsal lesion of the 36 week old ostrich (Figure 9) confirms erosion of the superficial horny layer and dermis of the skin extending deep into the sub-dermal layer with evidence of chronic inflammation and fibrosis.

There is also evidence of tissue necrosis and destruction. In the forgoing the extremely abrasive effects of the concrete floor on the tarso-metatarsal pads of especially the older and heavier ostrich are vividly demonstrated. This does raise serious questions about the suitability of concrete floor for the medium and long term rearing of the bird.

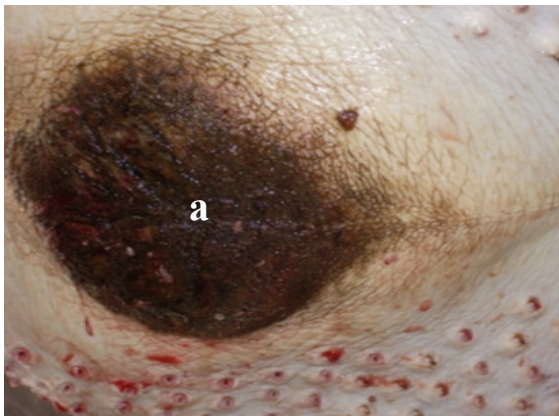
In the abovementioned, the extremely abrasive effects of the concrete floor on the tarso-metatarsal pads of especially the older and heavier ostrich are vividly demonstrated. This does raise serious questions about the suitability of concrete floor for the medium and long term rearing of the birds.

Figure 10: and 11 show the gross appearance of the sternal callosities of the 24 and 36 weeks ostrich respectively raised on concrete floor. At 24 weeks there were evidence of skin erosion at the sternal callosity. The development of corrugation and pitting is evident in the sternal callosity of the 36 weeks ostrich indicating an increase in erosive

trauma at this weight bearing area as the bird ages.



**Figure 10:** Ventral sternum of 24 week old ostrich reared on concrete floor showing: a, sternal callosity



**Figure 11:** Ventral sternum of 36 week old ostrich reared on concrete floor showing: a, sternal callosity with corrugation

Given the extent of erosion into the soft tissues of the subcutis, there would be pain and discomfort associated with the lesions developing on the tarso-metatarsal pad of the 36 weeks old ostrich on concrete floor. Grossly and microscopically, the erosive effects of the concrete floor are demonstrated by the present study to become more severe as the birds get older and heavier. Carvalho *et al.* (2004) found that the change in pressure distribution pigs with claw problems walking on hard concrete floor leads to lesions at the sole of the claw which tend to reach the soft tissues. Older sows and boars are particularly predisposed to this type of problem. There is pain and discomfort associated with locomotion by such animals which lead to decrease in weight gain and thus implies on animal welfare (Carvalho *et al.* 2004). Ostriches reared on concrete floor also

showed reduced weight gain compared to ostriches reared on soil floor (Waugh *et al.*, 2006)

Figure 12 shows the planter digital cushion of the ostrich reared on concrete floor. The skin is smooth and the horny featherlike projections observed on the birds kept on soil floor are absent suggesting that erosion beyond that seen in the ostriches raised on soil floor was occurring. The highly developed planter digital pad (Speer, 2011) allows for normal atraumatic locomotion even on concrete floors. At rest, however the ostrich assumes sternal recumbency for extended periods of time (Speer, 2011).

Over this rest period anecdotal evidence suggests (the present study) that the sternal and tarso-metatarsal callosities at the weight bearing points absorb the greater amount of the pressure exerted by the body weight of the bird. This despite lack of specialized shock absorbing mechanism at these weight bearing sites compared the planter digital areas of the bird. This would therefore dictate the need for a softer and more yielding surface for the long term keeping of the ostrich.

On concrete floors, extended periods of sternal recumbency and therefore periods of sustained pressure on the sternal and tarso-metatarsal callosities will likely lead to sustained periods of tissue ischemia and consequently degeneration and necrosis (Figures 8 and 9). The sternal and tarso-metatarsal callosities are therefore prone to be subjected to erosive trauma on concrete or other similarly hard and unyielding surfaces.

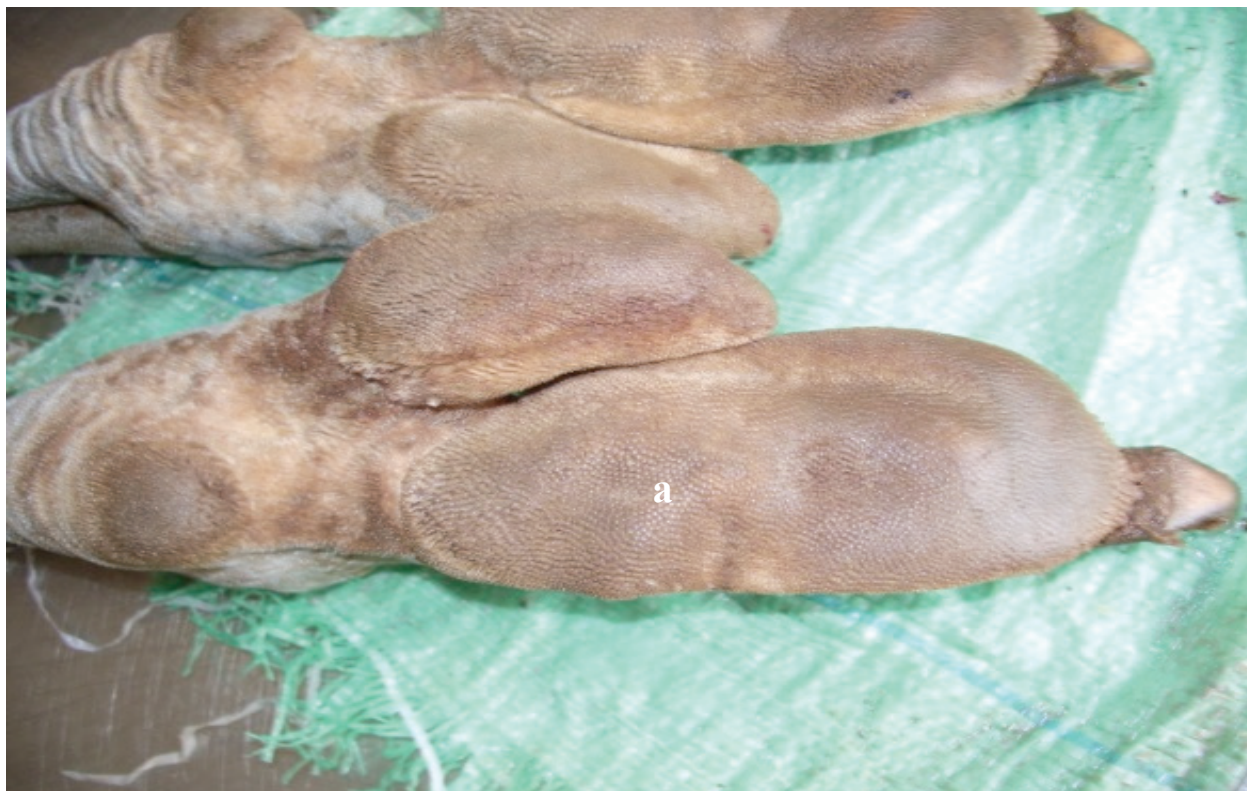## **CONCLUSIONS**

The results clearly demonstrate that holding ostriches on concrete floor for 24 weeks and beyond leads to increasingly severe, erosive trauma of the weight bearing points, especially the sternal and tarso-metatarsal callosities and compromised the welfare of the birds. In contrast the skin of ostriches held on soil floors for a similar time period remained intact and demonstrates the superiority of the usually softer soil floor over the hard and unyielding concrete floor as a surface for the long term rearing of ostriches.

Based on the findings of this study and in the interest of the welfare of the birds, ostriches should not be reared on concrete floors for extended periods of time unless cushioned by some appropriate material

## **ACKNOWLEDGEMENTS**

The authors acknowledge Research and Publications Committee for funding this project



**Figure 12:** Planter digital pad of the 36 week old ostrich reared on concrete floor. a= smooth horny surface layer of the digital pad

**Conflict of Interest** None

## REFERENCES

- Ackerman, T. (2011).** Effects of flooring on lameness of dairy cattle. American Dairymen  
<http://www.americandairymen.com/articles/effects-flooring-lameness-dairy-cattle>
- Aganga, A.O., Aganga, A.A., Modisa, L.G and Dub, S.N. (2000).** Ostrich Inspection and Nutrition. Government Printers, Gaborone, Botswana.
- Carvalho, V. C. (2004).** Effects of trimming on dairy cattle-hoof pressure distribution and weight bearing dynamics during the stance phase. Doctorate's Dissertation, University of Florida Library, Gainesville.
- Carvalho, V. C.; Naas, I. A., Neto, M. M. and Souza, S. R. L. (2009).** Measurement of pig claw pressure distribution. *Biosystems Engineering* 103: 357-363.
- Dellmann, H. D. and. Brown, E.M (1976).** Veterinary Histology. Lea and Febiger, Philadelphia.
- Graunke, K. L. Telezhenko, E; Hessel, A; Bergsten, C. and Loberg, J. M. (2011).** Does rubber flooring improve welfare and production in growing bulls in fully slatted floor pens? *Animal Welfare*. 20, 2: 173-183
- Huchzermeyer, F. W. (1994).** Ostrich Diseases. Gutenberg Book Printers, Pretoria.
- Kreibich, A. and M. Sommer, (1995).** Ostrich Farm Management. Landwirtschaftsver GmbH, Munster-Hilt up
- Mackie, R.I. (2002).** Mutualistic Fermentative Digestion in the Gastrointestinal Tract: Diversity and Evolution. *Integrative and Comparative Biology*. 2: 319-326
- Muller, G. H. and Kirk, R. W. (1976)** Small animal Dermatology. W. B. Saunders Company. Philadelphia.
- Mushi, E. Z., Chabo, R.G., Modisa. L and Binta, M.G. (1997).** Ostrich Farming in Botswana Government Printers, Gaborone.
- Speer, B. L. (2011).** Ratite Neuromuscular Diseases.  
<http://www.netpets.org/birds/healthspa/vet/ratite.html>

Waugh et al (2013) Changes occurring at weight bearing points of ostrich induced by soil or concrete floors. *Bots. J. Agric. Appl. Sci* 9 (Issue 1)41-48

**Waugh, E.E., Aganga, A. A., Seabo, D., Omphile, U.J. and Tsopito, C.M (2006).** Growth Rate and Feed Conversion Rate of Ostriches Fed Ration With or Without Grits in Botswana. *International Journal of Poultry Science* 5 : 470-473

**Waugh, E. E., Dzoma, B.M., Seabo, D., Aganga, A. A., Tsopito, C. M., Omphile, U. J., Sebolai, B. and Malela, L. (2007).** Gross Adaptive Morphologic Changes Occurring in the Gastrointestinal Tract Components of Ostriches fed Ration Including or Excluding Grit in Botswana. *International Journal of Poultry Science* 6: 271-275.